



PATIENT

Bella Fiona Kittay

SPECIES

Canine

BREED

Mix

SEX

Female Spayed

AGE

15 years

WEIGHT

17.5lbs

INTERPRETED BY

Maggie Machen
Lamy, DVM
DACVIM (Cardiology)

IMAGING PERFORMED BY

Pamela Harrigan,
RDCS

HOSPITAL NAME

Wood River Animal
Hospital

REFERRING VET

Dr. Fischer

INVOICE

24721

DATE

6/10/22

PRESENTING CLINICAL SIGNS

History: Recheck echo. History mild mitral valve disease - Stage B1, stable on prior echocardiogram 10/28/20, Mike Hickey, DVM, DACVIM-Cardiology. Currently: collapsing trachea; increased cough after exercise. Radiographs show mild bronchointerstitial pattern in lungs, unchanged from previous radiographs. ProBNP was 640 in March, is now 756. -Pertinent previous echo findings; LA 1.8 cm; LA:Ao 1.2; LV 2.08 cm

ECHOCARDIOGRAM FINDINGS

2D, m-mode, color flow and Doppler imaging is available.

Left ventricle: The LV diameter is normal with adequate myocardial function. LV wall thicknesses are normal.

Left atrium: The left atrium is normal.

Mitral valve: The mitral valve is mildly thickened with no prolapse into the left atrial lumen. Mild mitral regurgitation.

Aortic valve/aorta: The aortic valve is normal in morphology and mobility. Normal aortic outflow velocity; laminar flow. No aortic insufficiency.

Right ventricle: Normal right ventricular diameter and morphology indicating no overt evidence of pulmonary arterial hypertension.

Right atrium: Normal RA dimension.

Tricuspid valve: The tricuspid valve appears mildly thickening with septal prolapse and mild to moderate tricuspid regurgitation; normal velocity.

Pulmonic valve/pulmonary artery: The pulmonic valve is normal in morphology and mobility. No pulmonic insufficiency. Normal RVOT velocity; laminar flow.

Pericardium/other: No pericardial or pleural effusion noted. No obvious cardiac masses.

Heart rhythm: ECG reveals a sinus rhythm with an average HR of 130bpm.

2-Dimensional Measurements

Ao diam (cm)	1.4
LA diam (cm)	1.6
LA:Ao (Swe)	1.1
IVS thickness (cm)	0.6
LVID diastole (cm)	1.78
PW thickness (cm)	0.69
LVID systole (cm)	0.8
FS (%)	56

Doppler Measurements

PV Vmax (m/s)	0.63
AoV Vmax (m/s)	1.3
MR Vmax (m/s)	NM
TR Vmax (m/s)	2.2
TR PG (mmHg)	20

INTERPRETATION OF THE FINDINGS

The cause of the murmur is chronic degenerative valve disease causing mild mitral and mild to moderate tricuspid regurgitation. Compared to the prior study, there is no evidence of progression in left-sided disease with stable/normal left heart dimensions. Moderate TR is identified, which is not previously noted; however, no significant pulmonary hypertension is seen. No additional issues are noted in this study. Assessment of progression in the future will help predict long term prognosis, which is highly variable at this stage (B1).

Given these findings, the cough is unlikely to be cardiac in origin and primary respiratory causes should be considered. Consider further respiratory work up/treatment (hydrocodone, taper course of steroids, Enrofloxacin, TTW/BAL, etc.).



PATIENT

Bella Fiona Kittay

SPECIES

Canine

BREED

Mix

SEX

Female Spayed

AGE

15 years

WEIGHT

17.5lbs

INTERPRETED BY

Maggie Machen
 Lamy, DVM
 DACVIM (Cardiology)

IMAGING PERFORMED BY

Pamela Harrigan,
 RDCS

HOSPITAL NAME

Wood River Animal
 Hospital

REFERRING VET

Dr. Fischer

INVOICE

24721

DATE

6/10/22

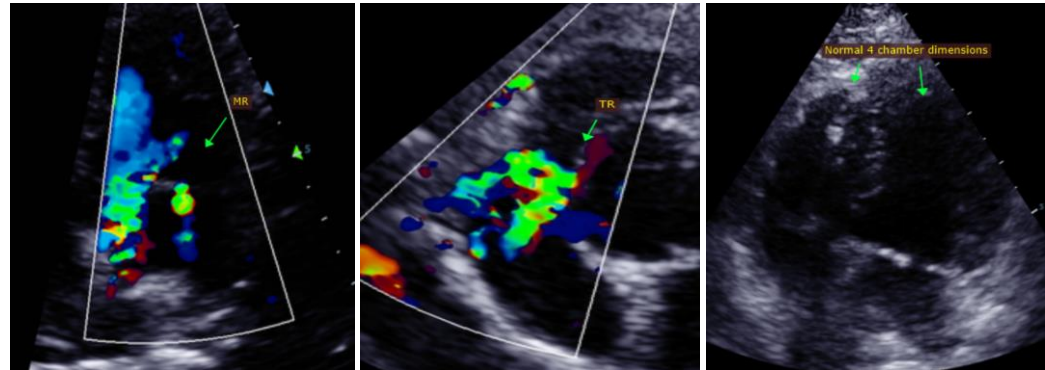
RECOMMENDATIONS

- Given these findings, no cardiac medications are clearly indicated.
- Omega fatty acid supplementation and mild salt restriction may be of some long-term benefit.
- Anesthetic risk is considered mild if needed. Cardiac protective drug choices (opioid/benzodiazepine premedication, propofol or alfaxalone induction, isoflurane gas) are recommended. Pre-oxygenate for 5-10 minutes prior to induction. Monitor for arrhythmias, hypotension, and hypoxia both intra and post-operatively and intervene as necessary. Mild IV fluid restriction is recommended to avoid fluid overload. Avoid heart rate stimulating drugs such as atropine unless clinically indicated.
- Monitor for development of a cough, labored breathing, exercise intolerance or collapse episodes.

PLAN

- Recommend conservative monitoring with a recheck echocardiogram in 6 months, sooner if any development of clinical signs.

IMAGES



The information and recommendations provided are based on the images presented by the referring veterinarian. No evaluation can be communicated regarding pathology that was not visible in the image/video clips provided.

Thank you for this referral. This report was generated using transcription software, and minor dictation errors may be present. If the clinical or image interpretation does not parallel your findings or if I can be of any further assistance, please contact me.

Maggie Machen Lamy, DVM
 Diplomate of the American College of Veterinary Internal Medicine (Cardiology)
 info@sonopath.com